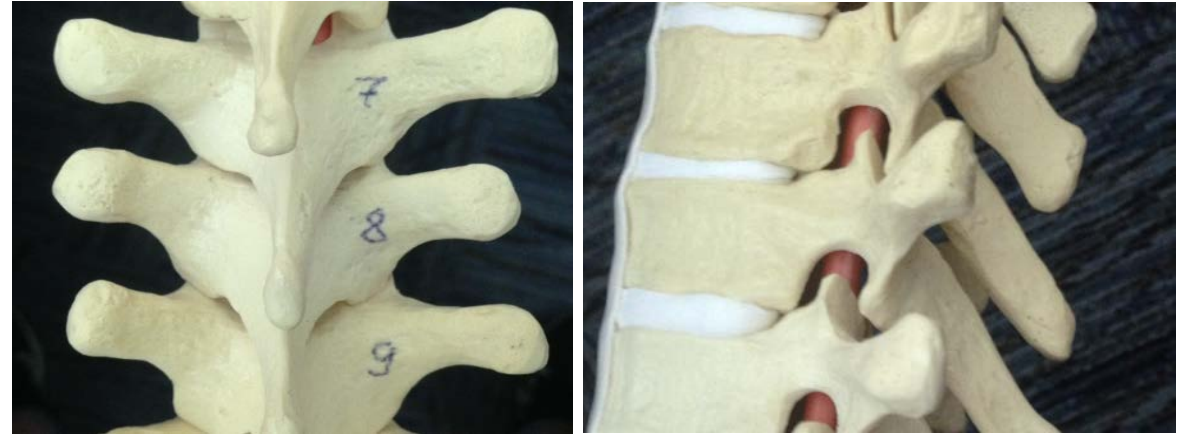

# Q1. When asked to do landmark based paramedian epidural at T7/8

1. One should outline the SP of T8 and enter needle lateral to it almost perpendicular to the skin surface
2. One should outline the SP of T7 and enter needle lateral to it almost perpendicular to the skin surface
3. One should outline both SP of T7 and T8 and enter the skin inbetween

# A1. When asked to do landmark based paramedian epidural at T7/8

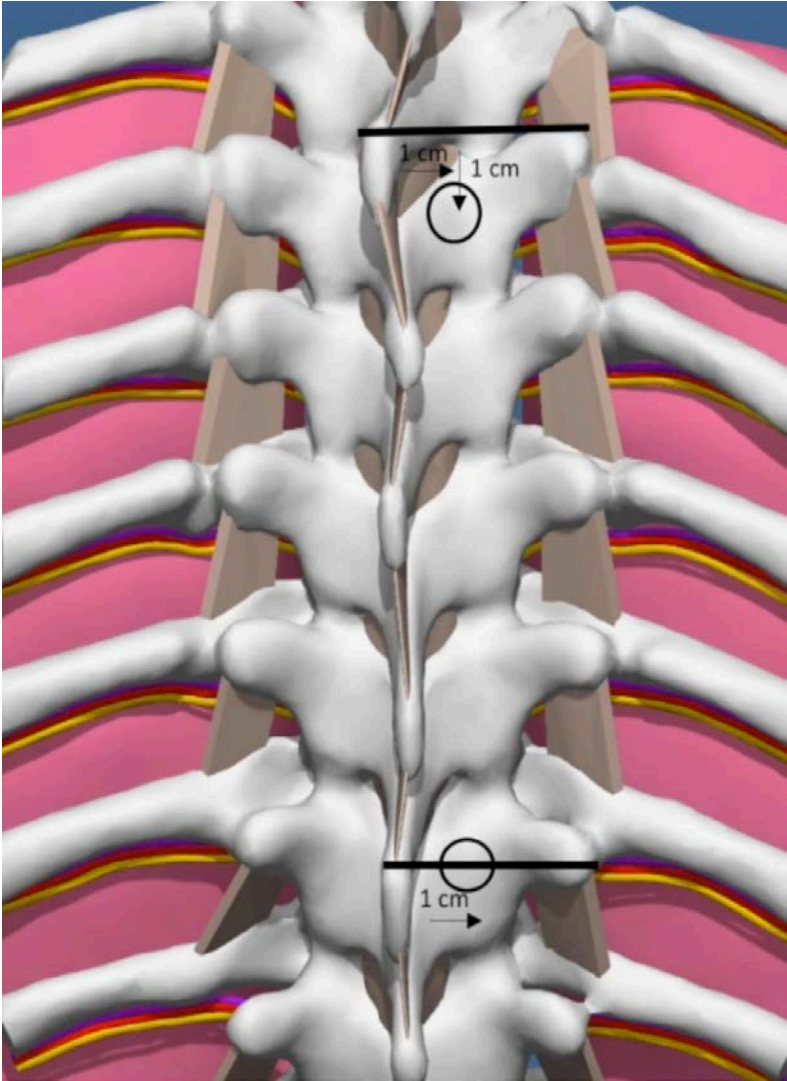
- One should outline SP of T7 and enter needle lateral to it almost perpendicular to the skin surface



2 is correct. We outline the SP of the cranial vertebrae and use it to determine the skin projection for the safe landing on the lamina of vertebrae below that are at the level of SP above, due to the fact that the SP in mid-thorax is steeply angulated down

**Q2. When marking a skin projection for safe landing relative to the upper edge of the SP, how is the upper thorax different from the mid thorax?**

1. No difference, one can mark a skin for safe landing 1 cm lateral and 1 cm caudad from the mid point of the upper edge of the SP
2. Main difference is in the caudad distance: we mark less in the upper thorax and more down in the mid thorax
3. Main difference is in the lateral distance: we mark the skin more lateral in the mid thorax
4. Main difference is in the caudad distance: we mark less in the mid thorax and more down in the upper thorax

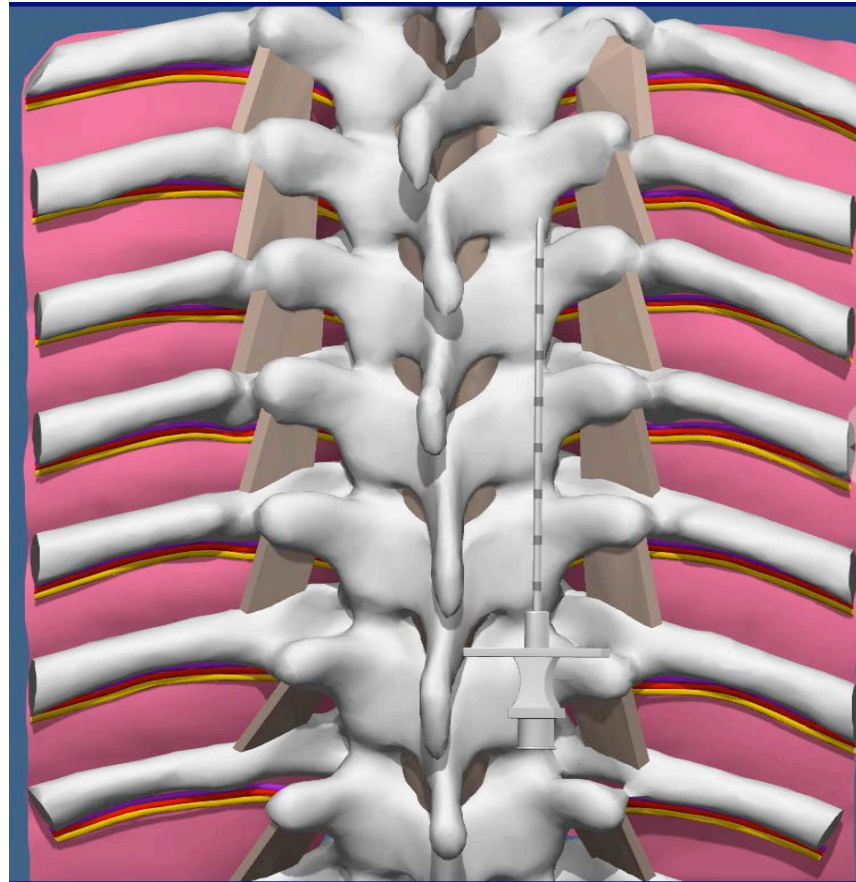
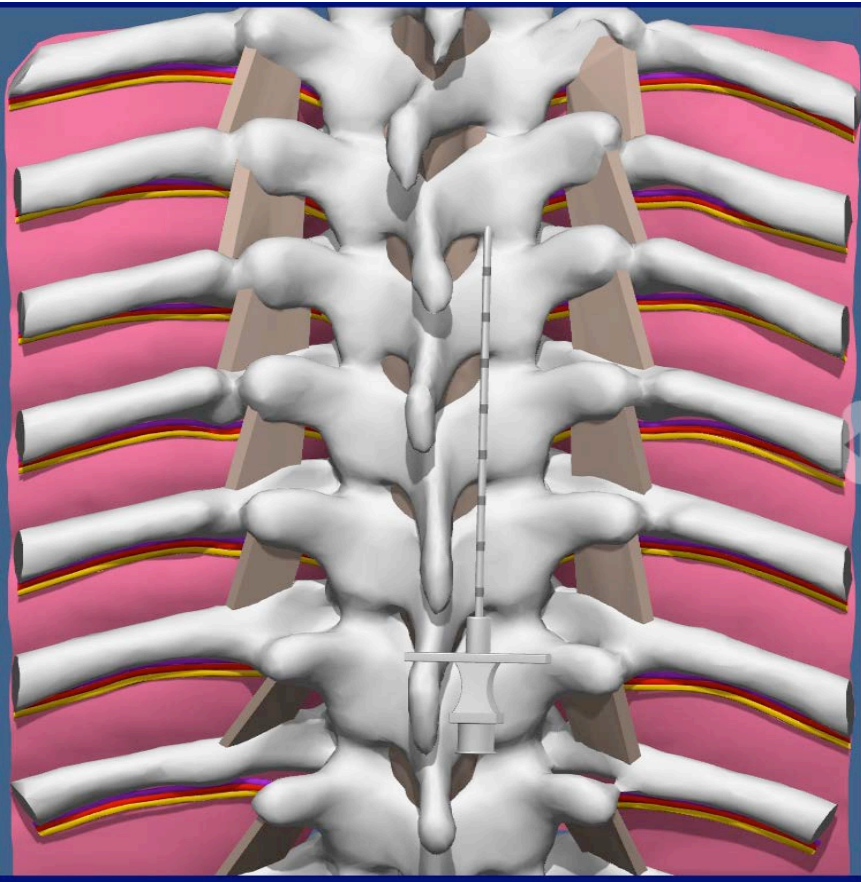


**A2. When marking a skin projection for safe landing relative to the upper edge of SP, how is the upper thorax different from the mid thorax?**

- Main difference in the caudad distance: we mark less in the mid thorax and more down in the upper thorax

**Q3. When marking a skin projection for a safe landing the correct distance from the midline should be**

1. Less than 2 cm to avoid accidental lung injury
2. More than 1 cm from midline to avoid inadvertent placement of the needle into intralaminar space on the first pass
3. 1.5 cm between the two



The left needle is 1cm from the midline and the right needle is 2cm from the midline. Therefore, the safe landing distance is between those two distances at 1.5cm

A3. When marking a skin projection for a safe landing the correct distance from midline should be

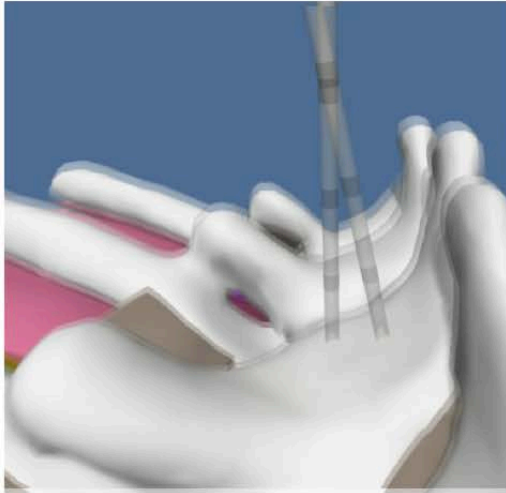
1. Less than 2 cm to avoid accidental lung injury
2. More than 1 cm from midline to avoid inadvertent placement of the needle into intralaminar space on the first pass
3. **1.5 cm between the two**

**Q4. After a safe landing on the midlamina the recommended “lamina walk” of the needle is**

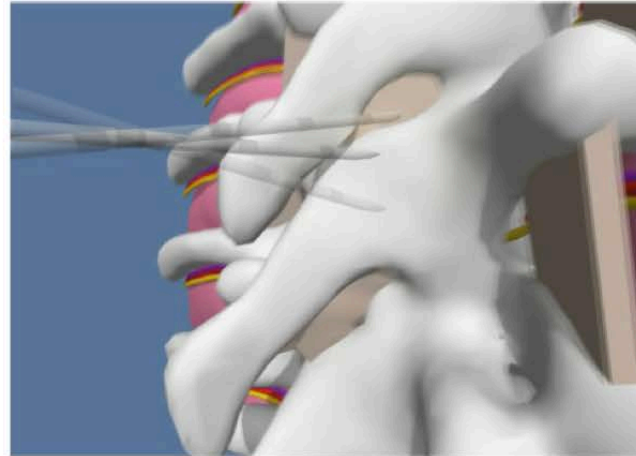
1. Medial/horizontal walk and then a vertical walk
2. Vertical walk and then a medial/horizontal walk
3. Diagonal walk up and medially



## Essence of the Technique

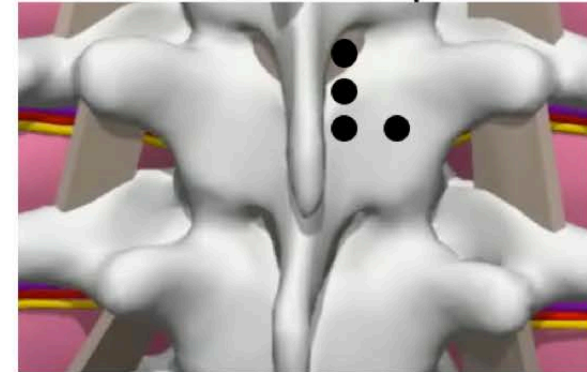


Horizontal Walk



Vertical Walk

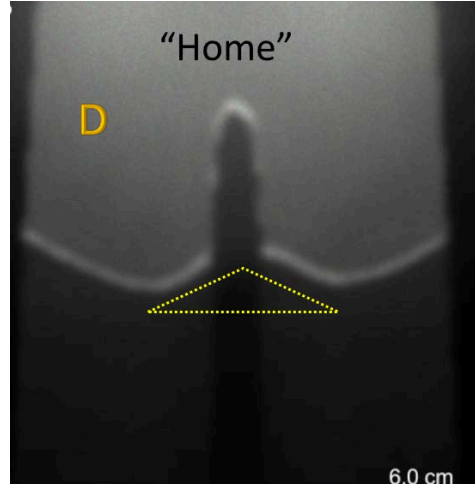
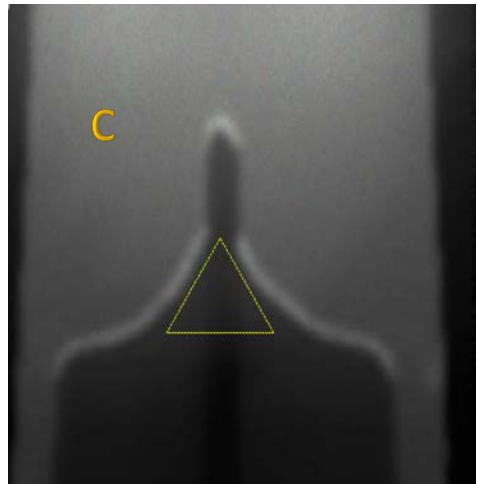
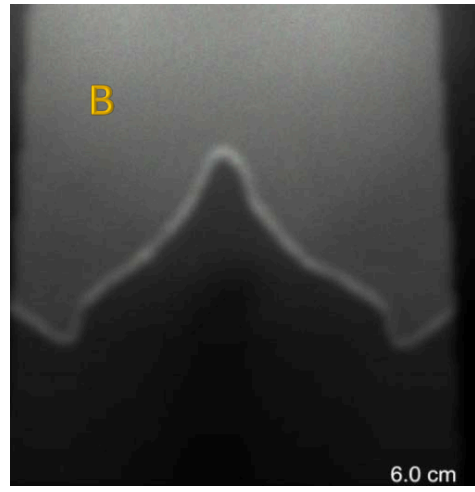

Typical trajectory from SL  
to Interlaminar space



**A4. After a safe landing on the midlamina the recommended “lamina walk” of the needle is**

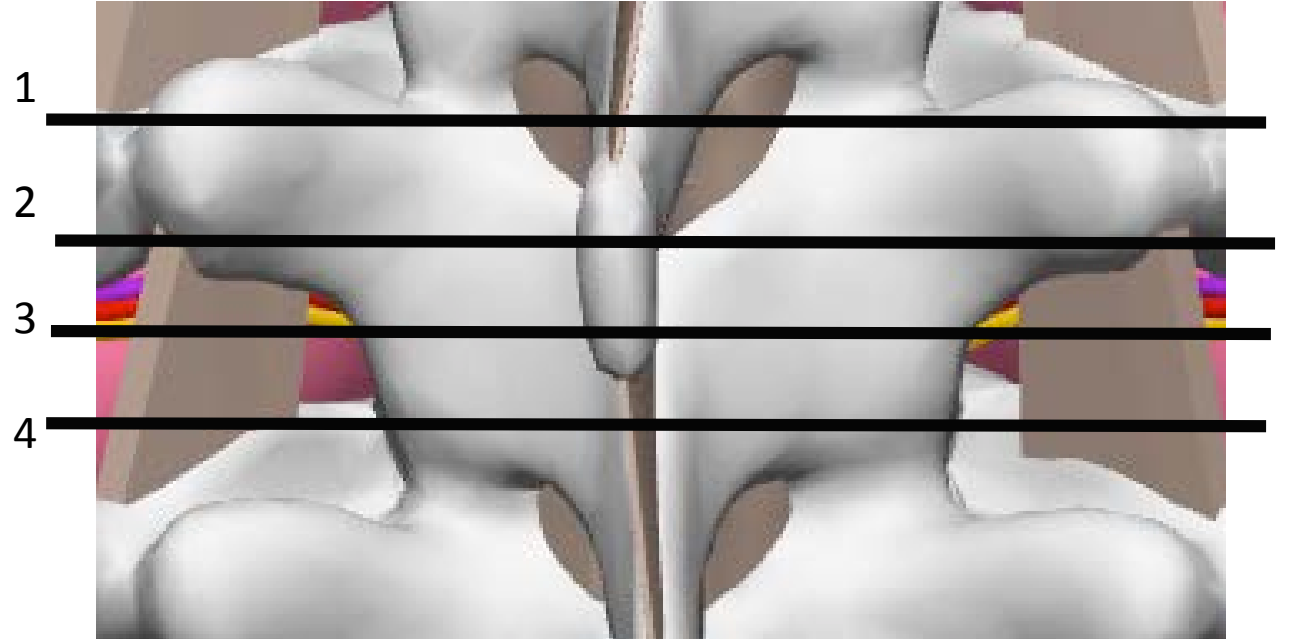1. Medial/ horizontal walk and then vertical walk

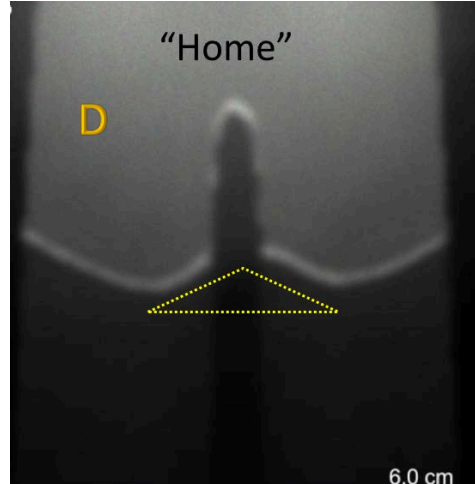
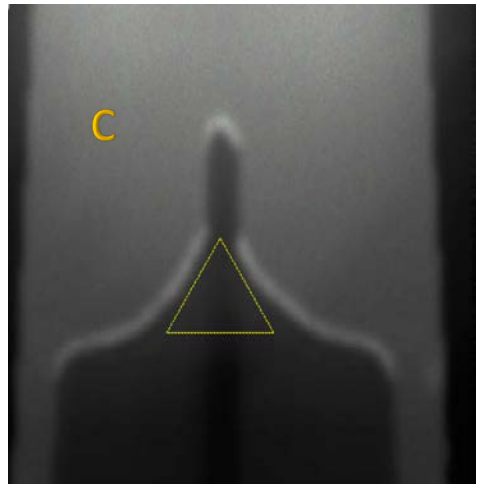
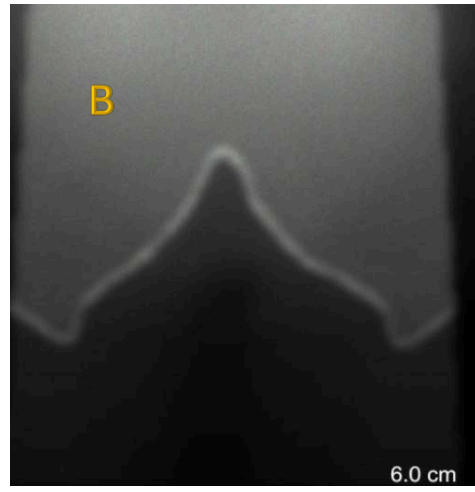





**Q5. Match the cross section on the left with the lines on the right:**

- 1). A2, B4, C3, D1
- 2). A3, B2, C1, D4
- 3). A1, B4, C3, D2
- 4). A1, B4, C2, D3





**A5. Match the cross section on the left with the lines on the right:**

A1, B4, C3, D2

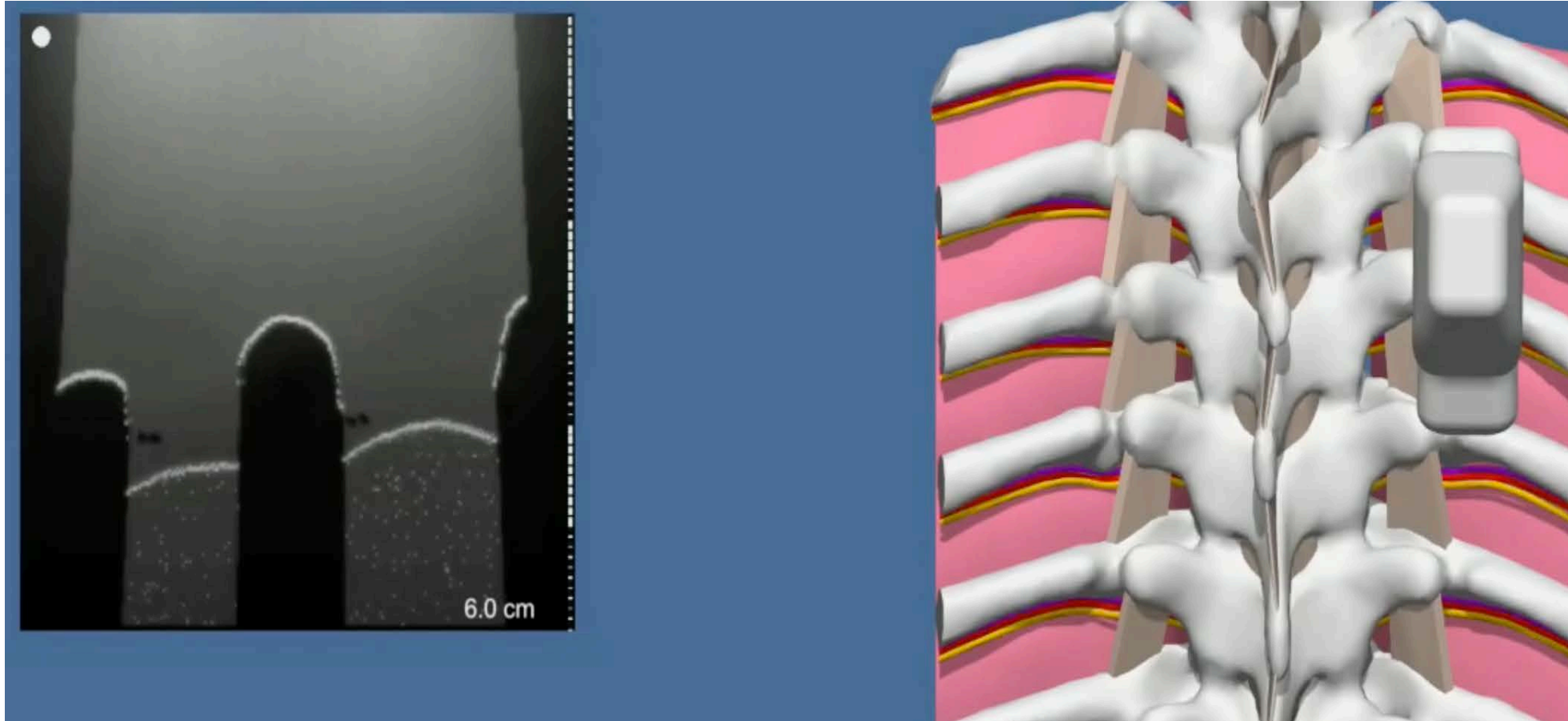


**Q6. When performing an US assisted epidural at T4/5, or US assisted TPVB at T5 what should you mark?**

- 1). Rib 6
- 2). Rib 4
- 3). SP5
- 4). Rib 5

A6. When performing an US assisted epidural at T4/5, or TPVB at T5 what should you mark?

- Rib 5



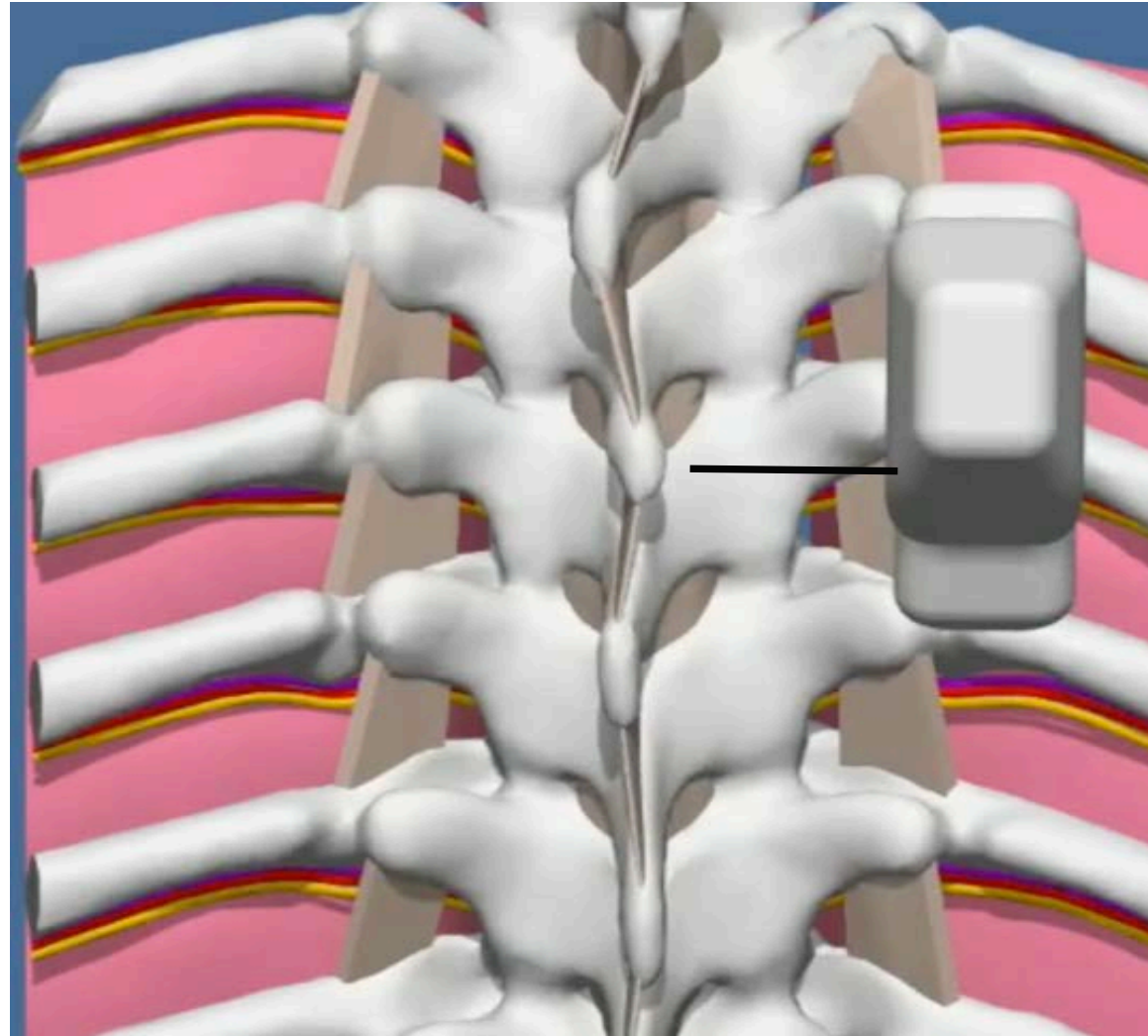
**Q7. If you use the sagittal view of the transverse process what part of the TP should you utilize as a surrogate marker for a safe landing on the mid lamina?**

1). Cranial

2). Caudad

A7. If you use the sagittal view of the transverse process what part of the TP should you utilize as a surrogate marker for a safe landing on the mid lamina?

- Caudad



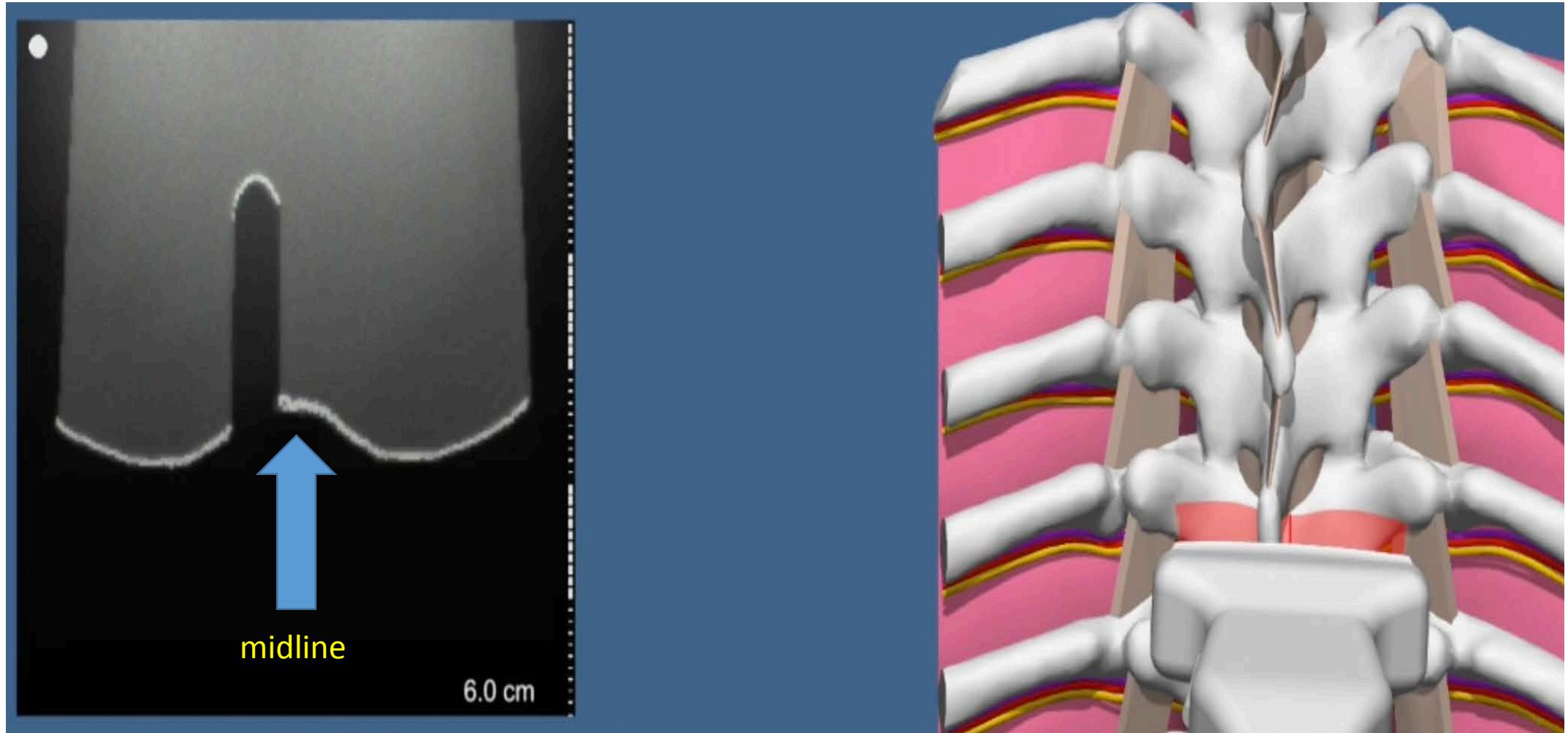
**Q8. When determining the midline with the US, for US assisted epidural the best practice is**

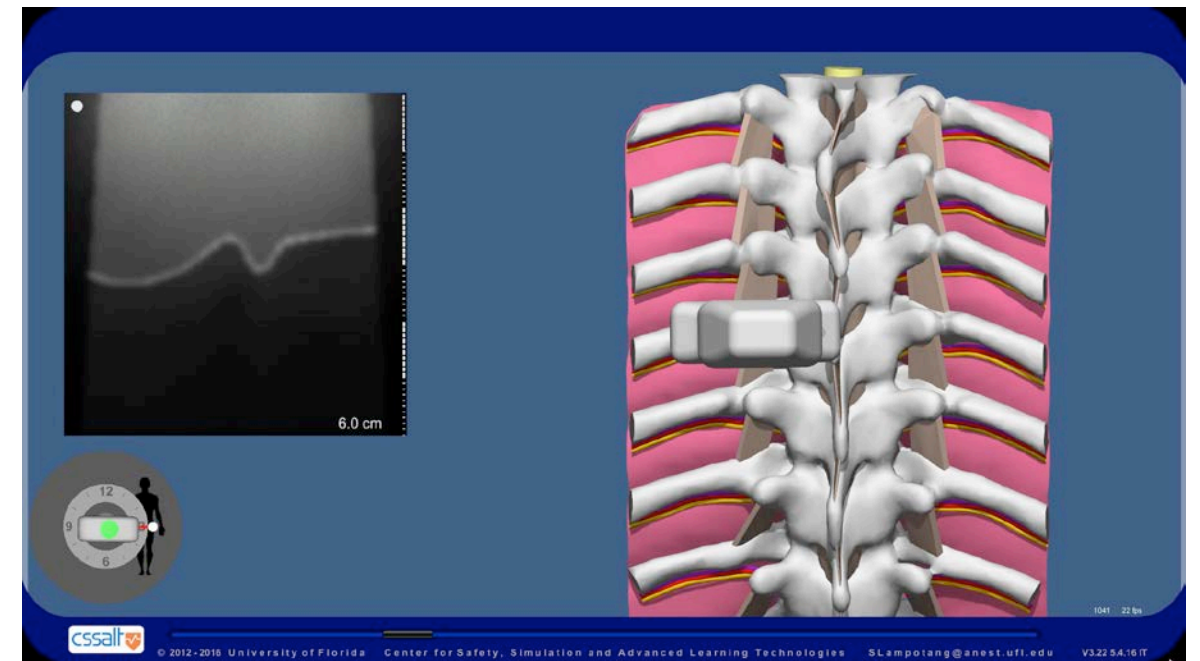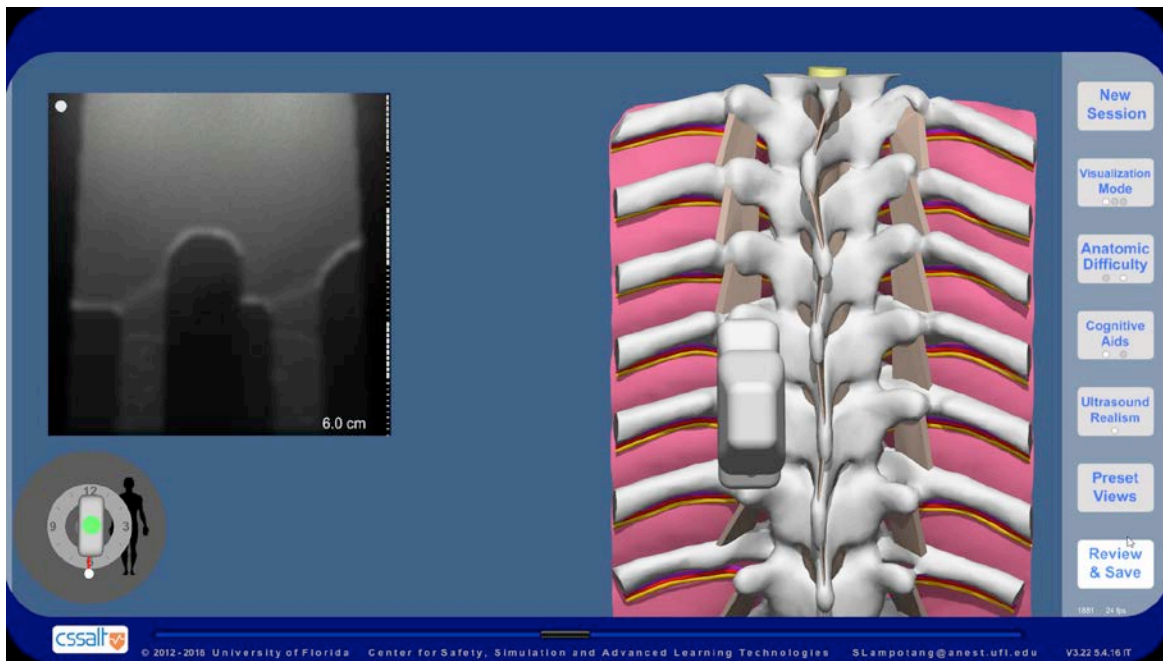
- 1). Use the image of the SP above
- 2). Use of the image of the lamina below
- 3). Use the image of the SP below



**A8. When determining the midline with the US for US assisted epidural, the best practice is**

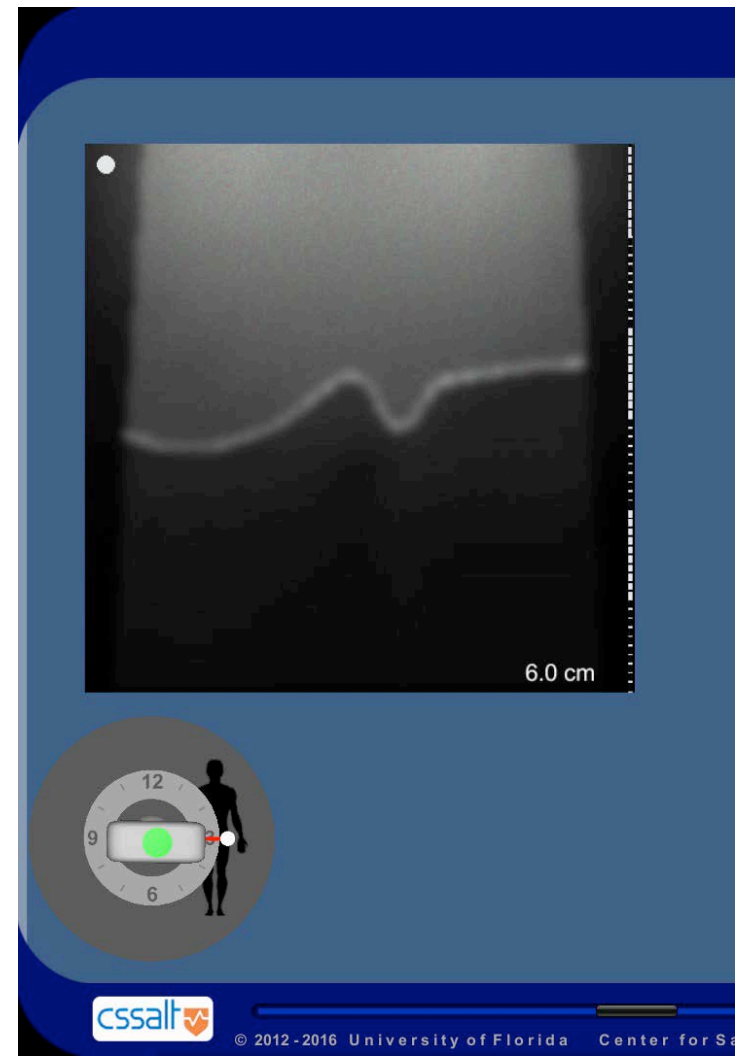
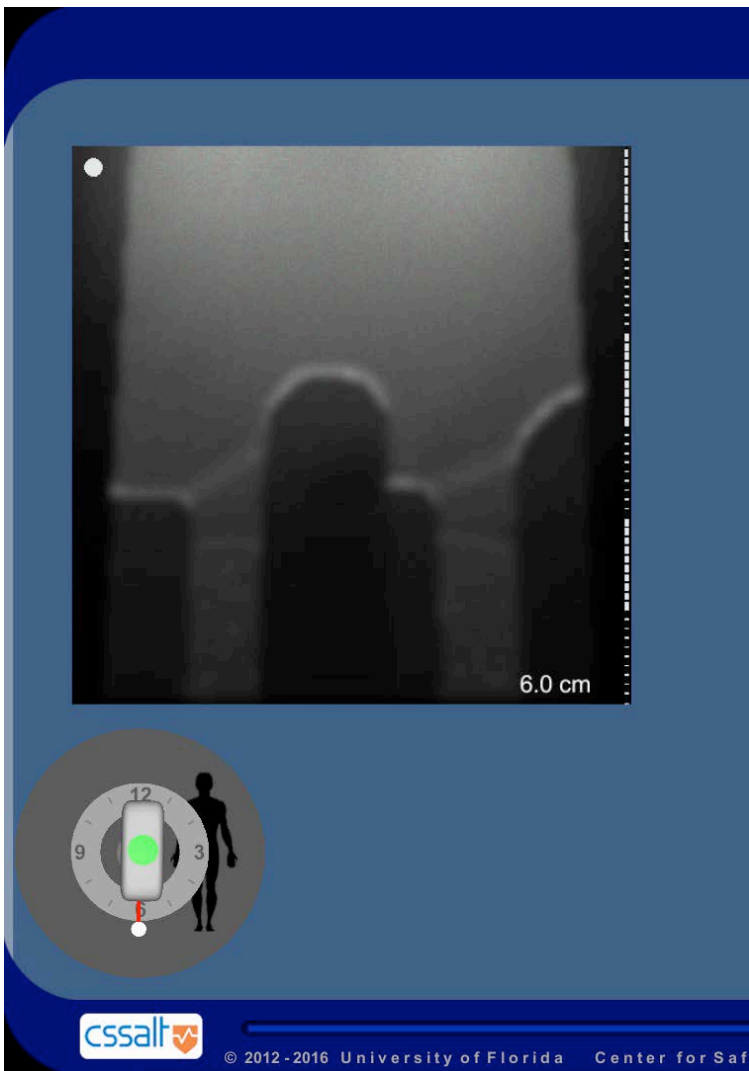
- Use of the image of the lamina below






### Q9. What is wrong with the following images?

- 1). The probe is rocked
- 2). The probe is tilted
- 3). The probe is orientated incorrectly
- 4). The probe is rotated 90 degrees




**A9. What is wrong with the following images?**

- The probe is orientated incorrectly





**Q10. If we are trying to mark the tip of the TP in a sagittal view, what is wrong with this image?**

- 1). The probe needs to be flipped 180 degrees
- 2). The image shows the root of the TP, rather than the tip of TP
- 3). The probe is rocked
- 4). The image shows the rib, rather than the tip of the TP




**A10. If we are trying to mark the tip of the TP in a sagittal view, what is wrong with this image?**

2). The image shows the root of the TP, rather than the tip of the TP



**Q11. What is Delta?**

- 1). 2
- 2). 3
- 3). 1.5
- 4). 4

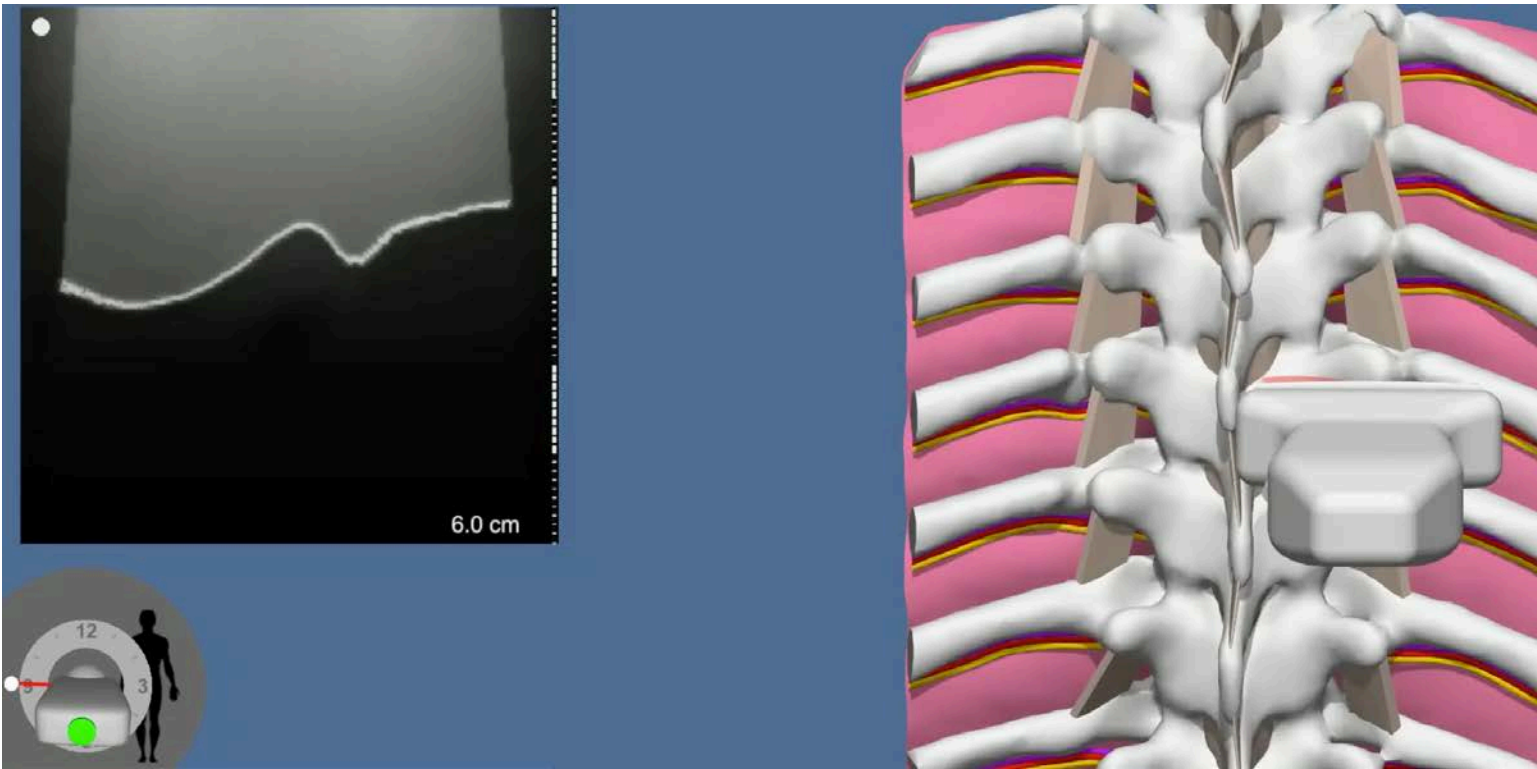


**A11. What is Delta?**

1). 2

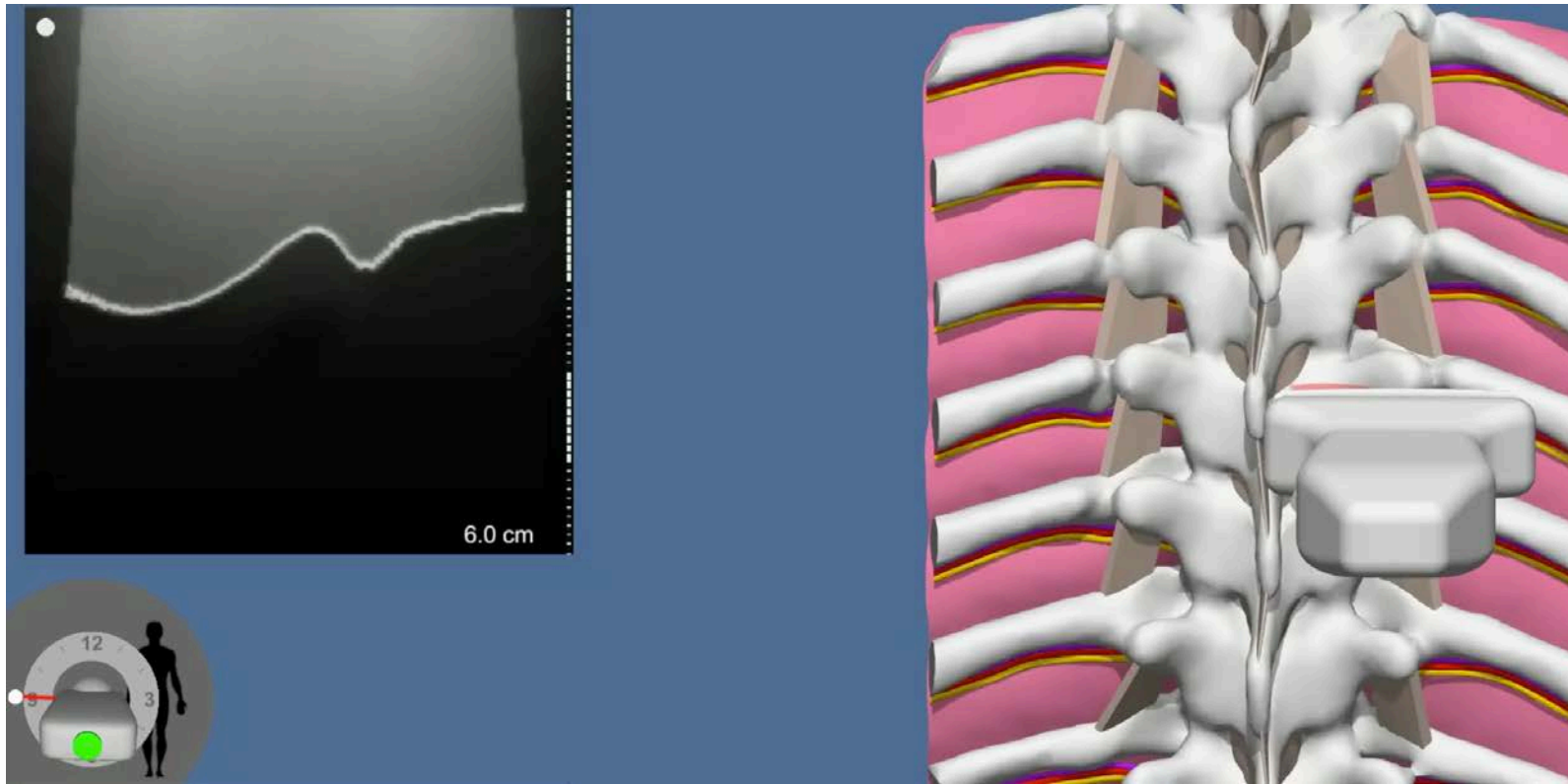
$$\Delta = 4 - 2 = 2$$





**Q12. What is the safe landing distance?**

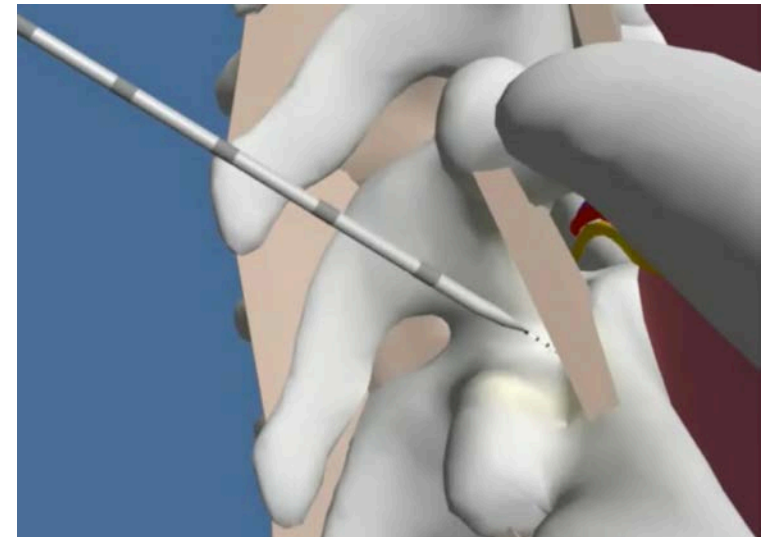
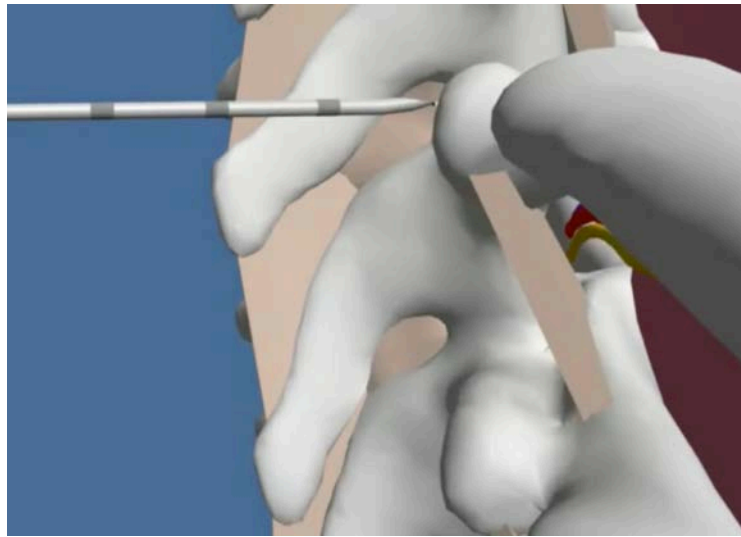
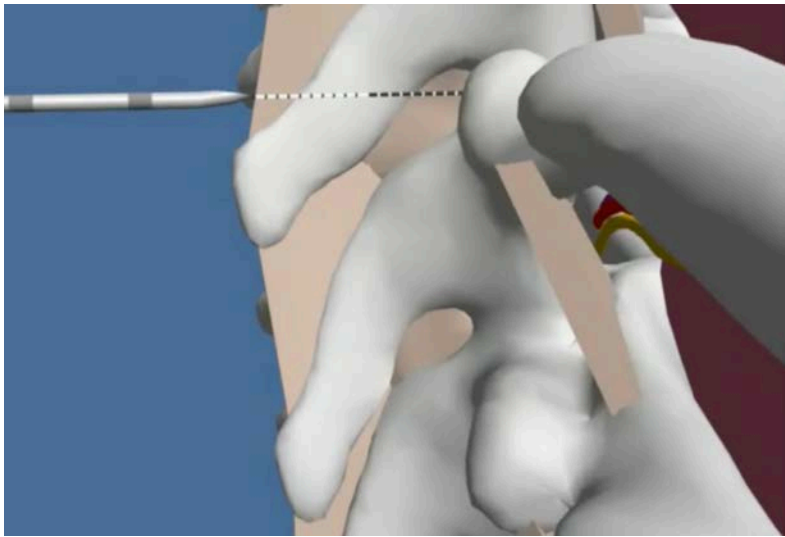
- 1). 2cm
- 2). 2.5cm
- 3). 3cm
- 4). Impossible to determine, you need additional scans



**A12. What is the safe landing distance?**

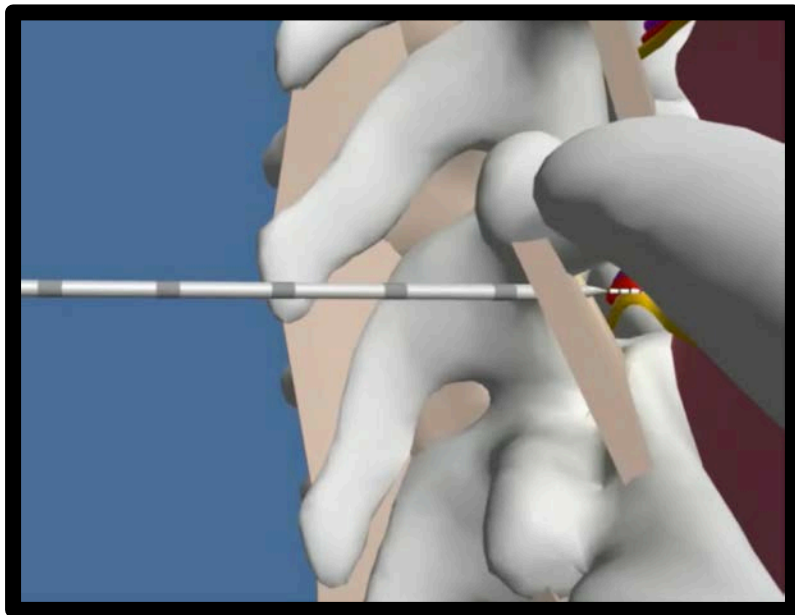
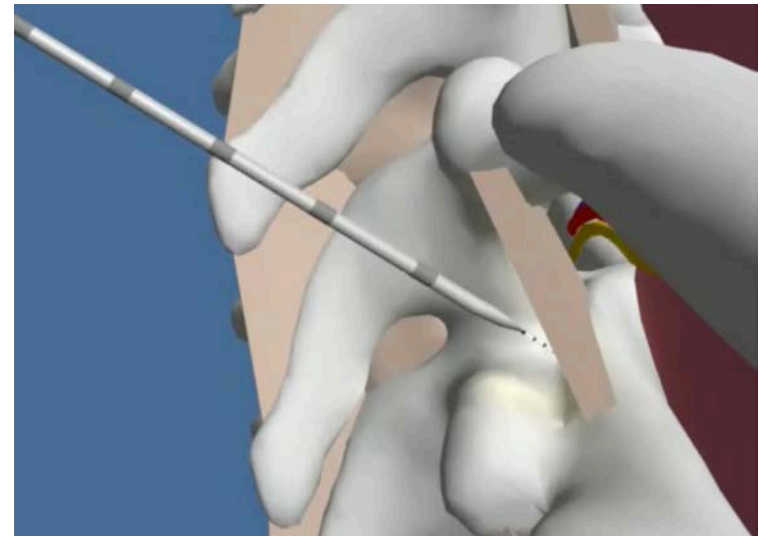
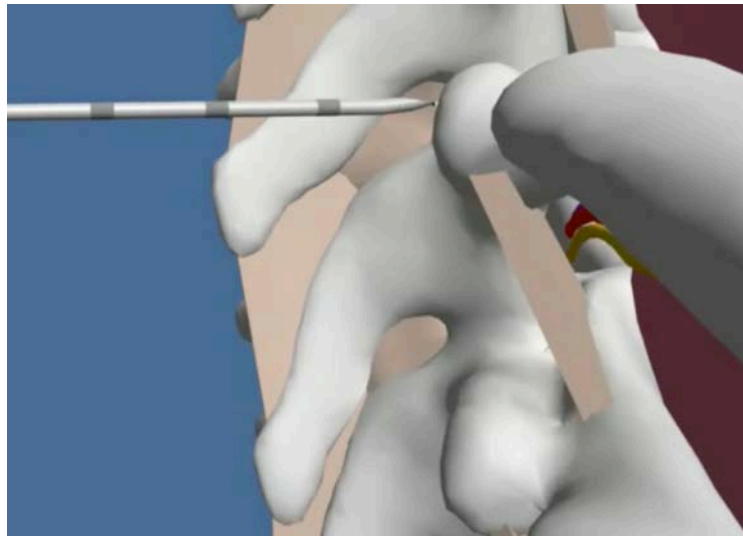
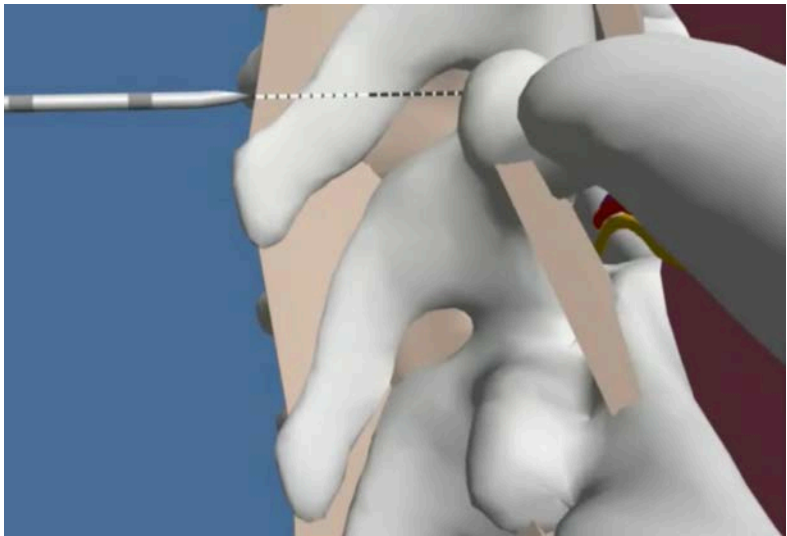
2.5cm

The safe landing distance is the distance between the skin, the tip of TP + 5mm.



**Q13. What is the problem?**

- 1). There is nothing wrong with this scenario
- 2). You landed too low on the TP and your angulation was too steep. Continue with the initial advancement.
- 3). You landed too high on the TP and your angulation was too steep. Your initial advancement may not be enough to get you into the paravertebral space. You may need secondary advancement, or a change in trajectory, or both. The final needle angulation should be close to a right angle.



**A13. What is the problem?**


You landed too high on the TP and your angulation was too steep. Your initial advancement may not be enough to get you into the paravertebral space. You may need secondary advancement, or a change in trajectory, or both. The final needle angulation should be close to a right angle.

**Q14. If you have no loss of resistance (LOR) after initial advancement (IA), what is the endpoint for secondary advancement (SA)?**

- 1). LOR
- 2). 5mm past the depth of IA, or LOR, whichever comes first. After that use US
- 3). 1cm past the depth of IA

**A14. If you have no loss of resistance (LOR) after initial advancement (IA), what is the endpoint for secondary advancement (SA)?**


- 5mm past the depth of IA, or LOR, whichever comes first. After that use US



**Q15. After obtaining this image, what are the proceeding steps?**

- 1). Slide the probe medially and slightly rotate it clockwise
- 2). Move the probe laterally and tilt it cephalad
- 3). Slide the probe laterally, then 1cm caudad, and then rock the probe forward
- 4). Tilt the probe caudad





**A15. After obtaining this image, what are the proceeding steps?**


Slide the probe laterally, then 1cm caudad, and then rock the probe forward


Acquire the “standard one image”

Slide the probe laterally

Slide the probe about 1cm caudad


Rock the probe forward





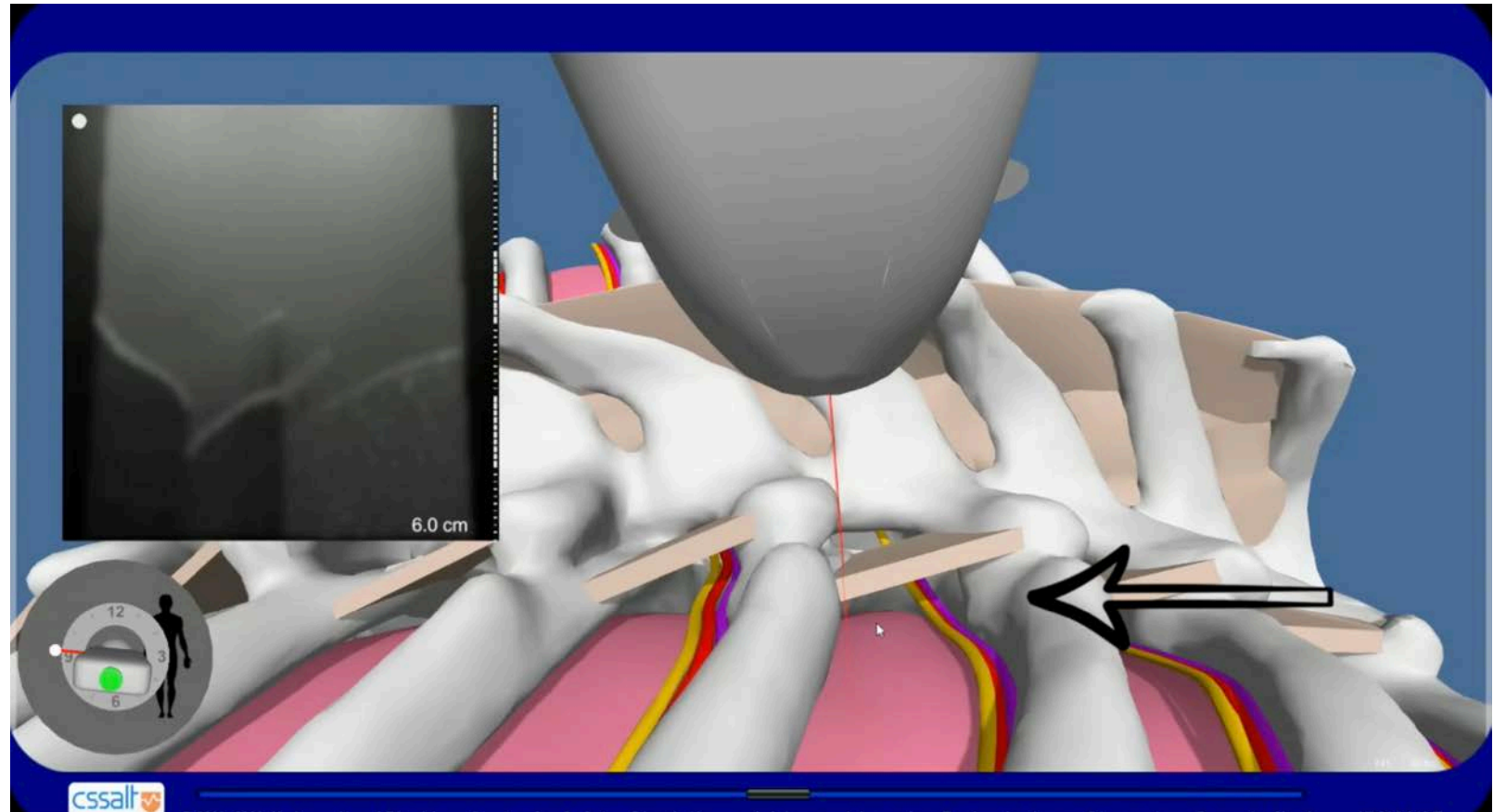
**Q16. What is wrong with this image for an US guided TPVB?**

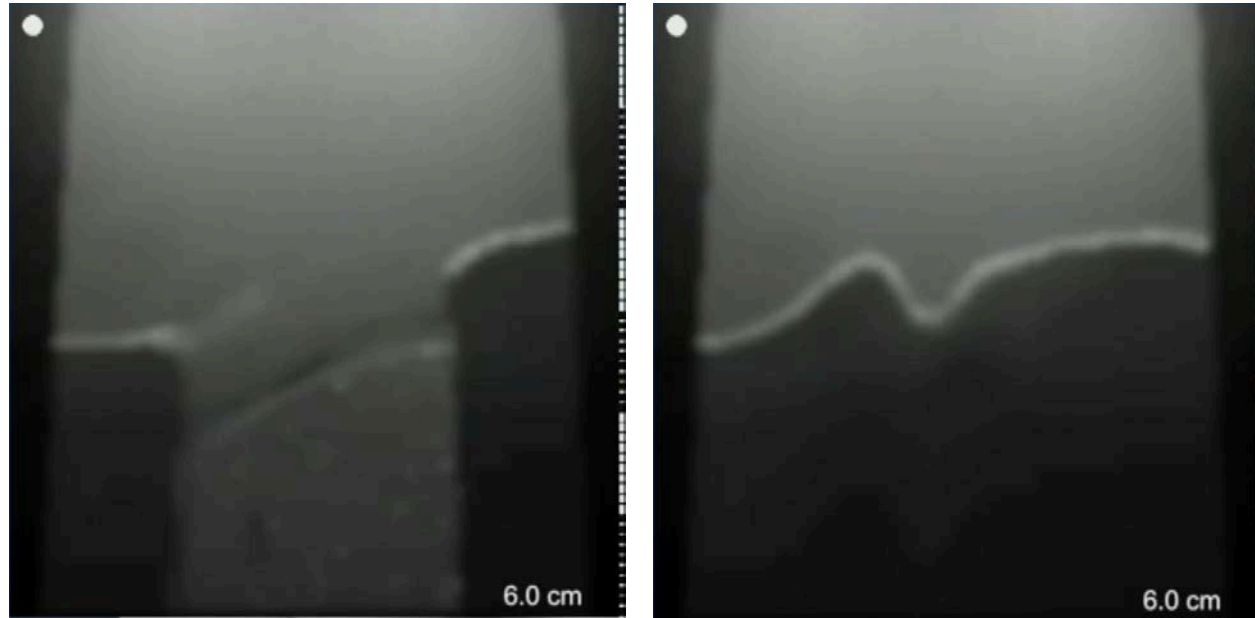
- 1). The image is too cephalad
- 2). The image is too caudal
- 3). The image is too medial
- 4). The image is too lateral



**A16. What is wrong with this image for an US guided TPVB?**

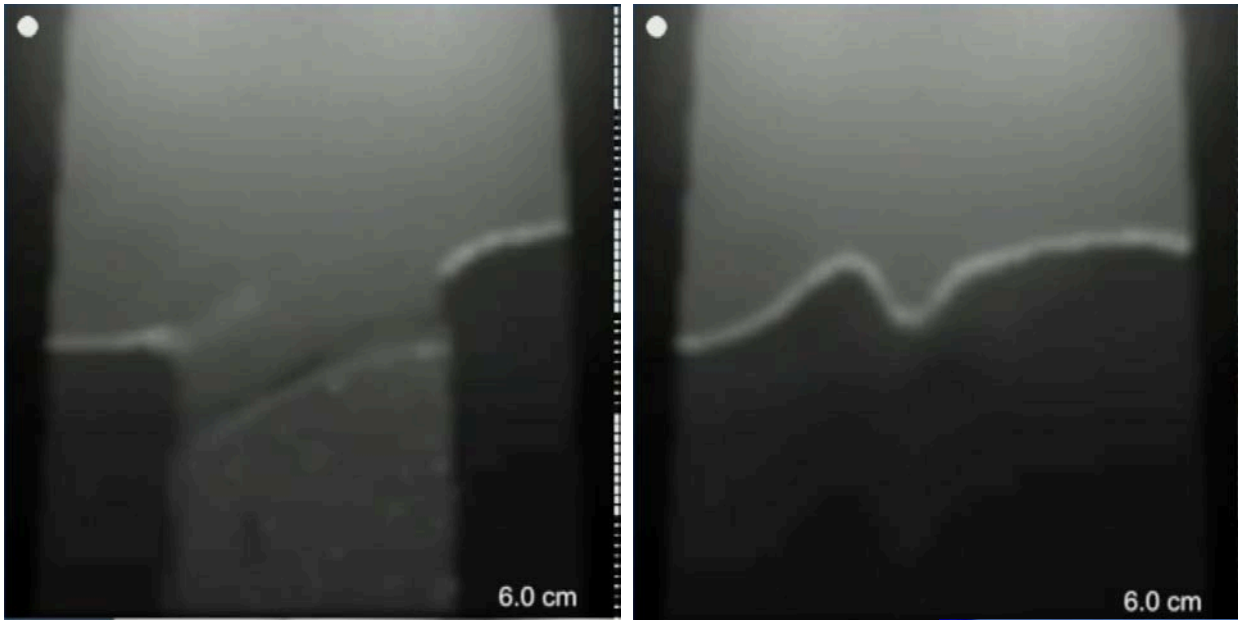
2). The image is too caudal





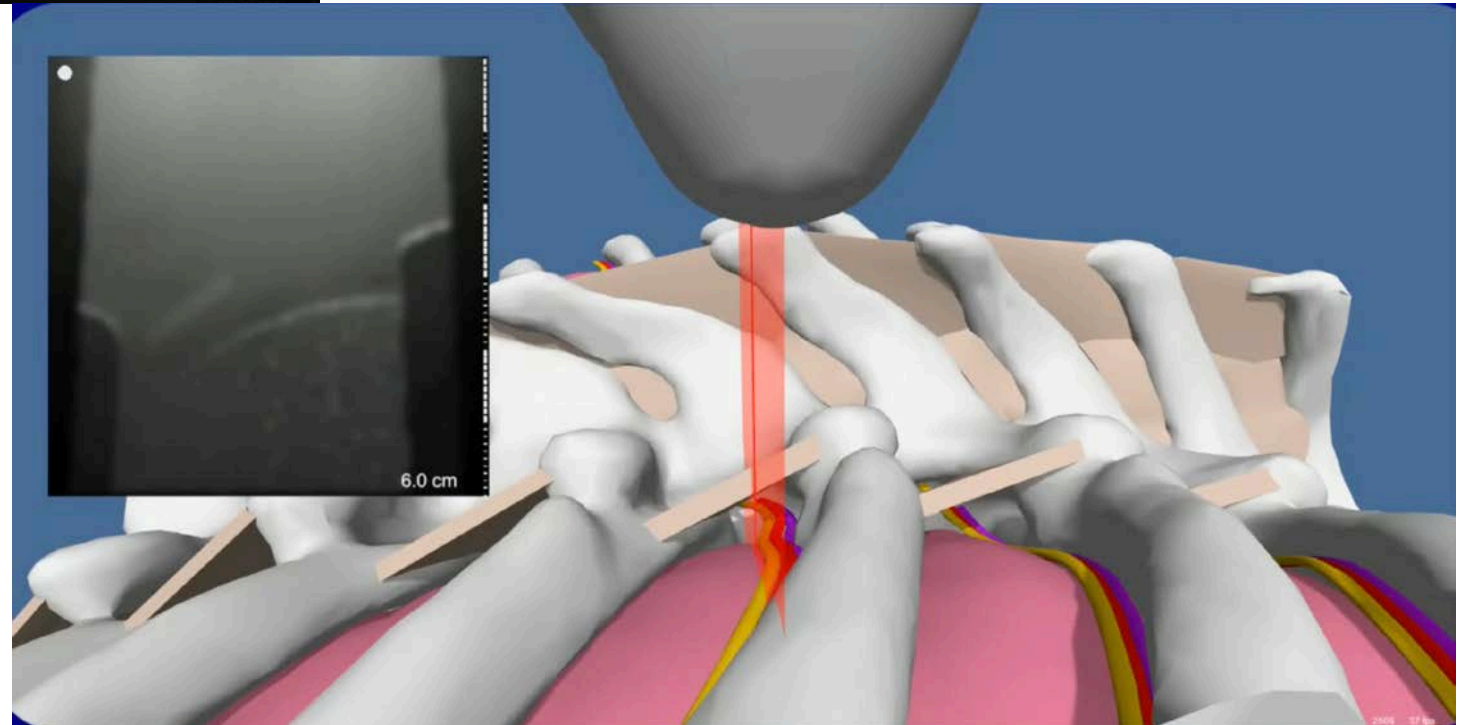
**Q17. Before you start needing for an US guided TPVB, we did a mini-slide. The image on the left turned into the image on the right. What is wrong with this situation and how do you fix it?**

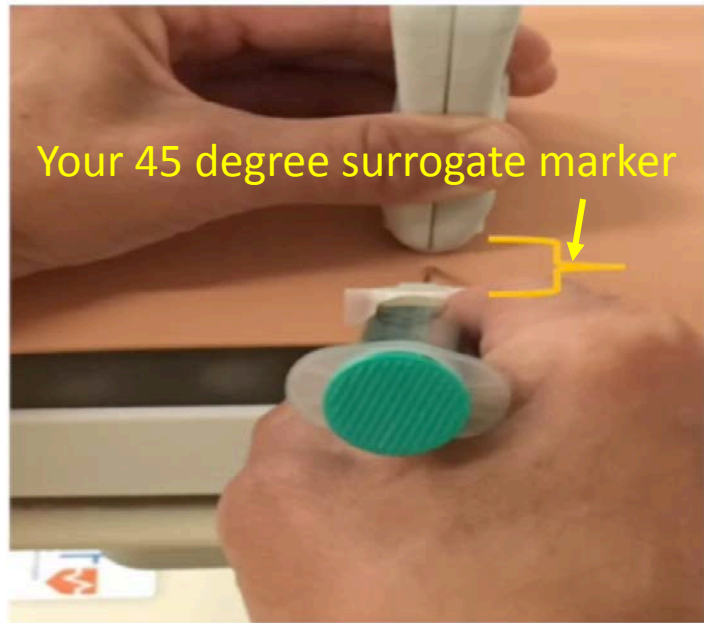- 1). The US probe is cephalad and there is not enough acoustic window for a mini slide. You should move the probe slightly caudad.
- 2). The probe is too medial. To fix this you need to rock the probe forward.



**A17. Before you start needing for an US guided TPVB, we did a mini-slide. The image on the left turned into the image on the right. What is wrong with this situation and how do you fix it?**


1). The US probe is cephalad and there is not enough acoustic window for a mini slide. You should move the probe slightly caudad.



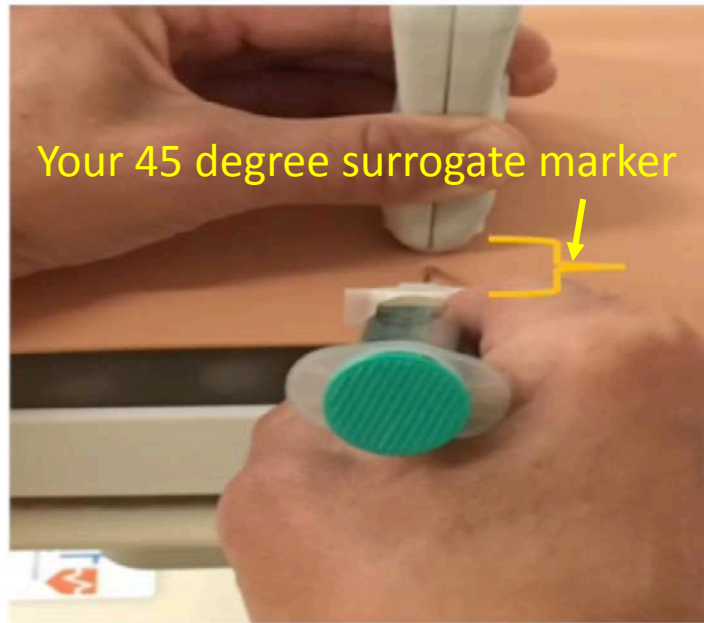

**Q18. What should you do with your needle to have the desired trajectory on the image below?**

- 1). Lift the hub
- 2). Slide the hub down
- 3). Move the hub to the left
- 4). Move the hub to the right









**A18. What should you do with your needle to have the desired trajectory on the image below?**

2). Slide the hub down








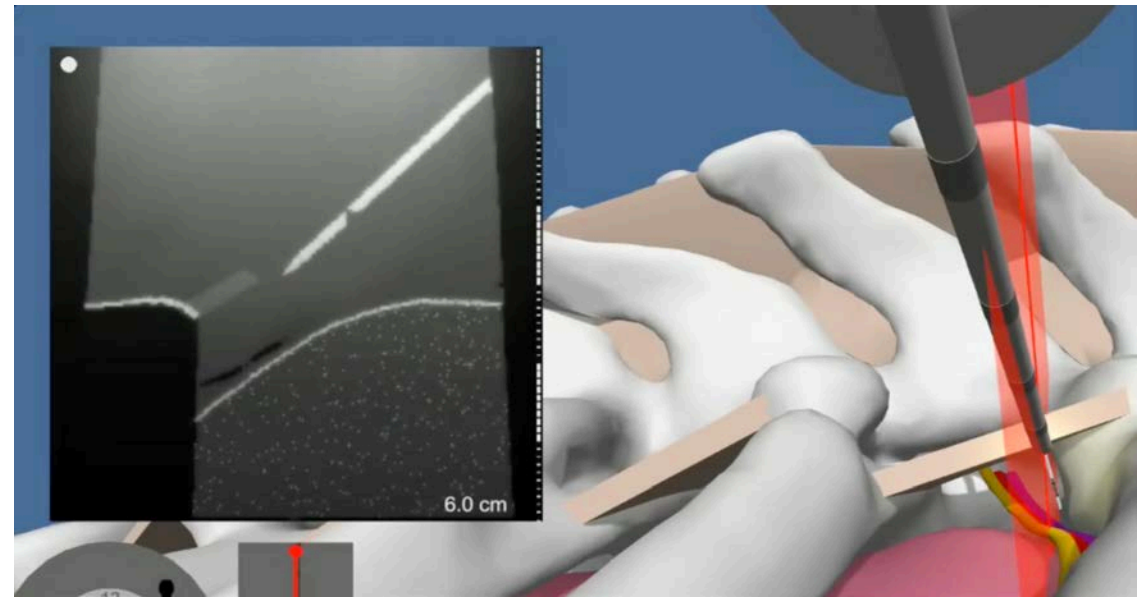
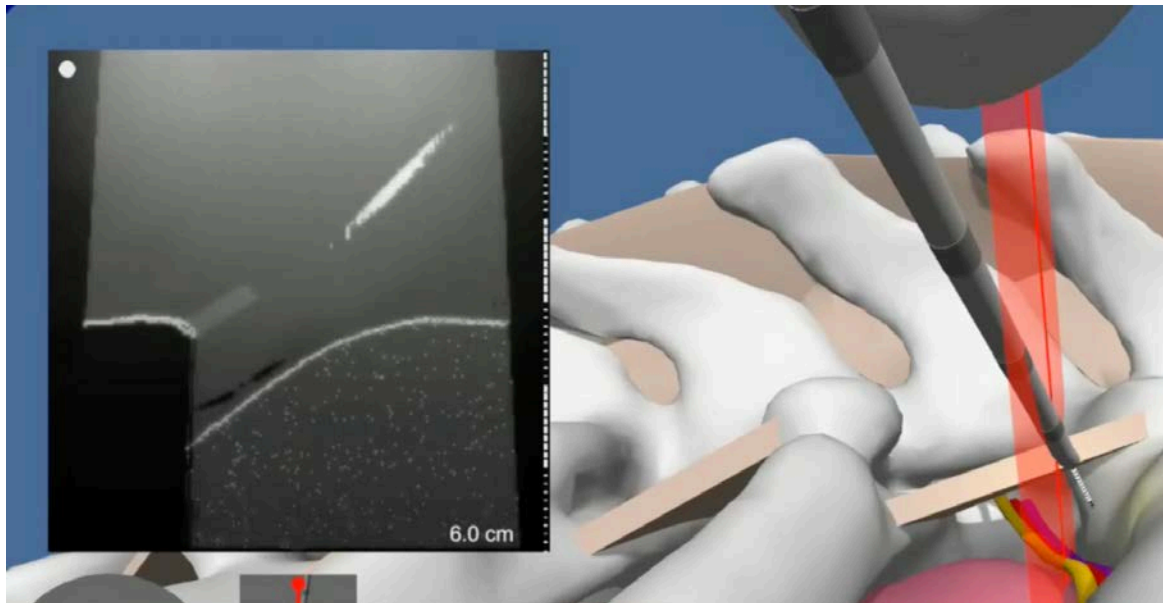
**Q19. What do you have to do to perfect your needle alignment?**

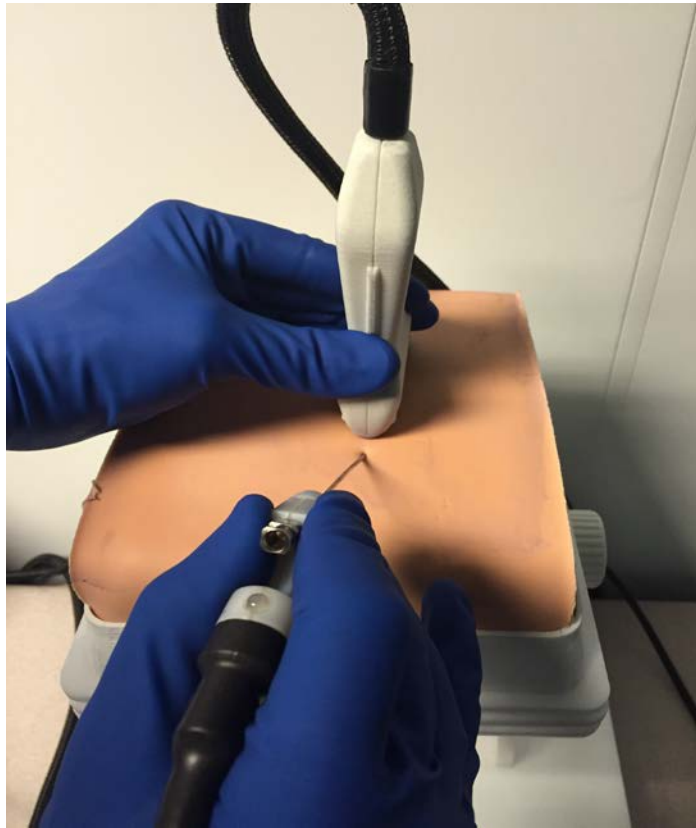- 1). Tilt the probe
- 2). Slide the probe to the left
- 3). Push laterally on the needle hub



A19. What do you have to do to perfect your needle alignment?

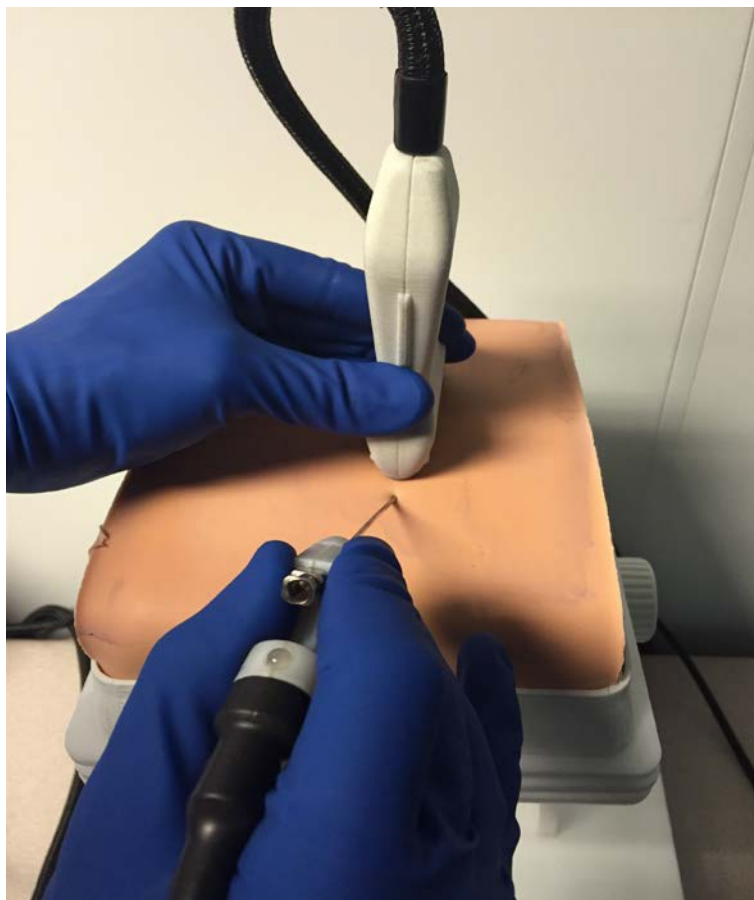
3). Push laterally on the needle hub





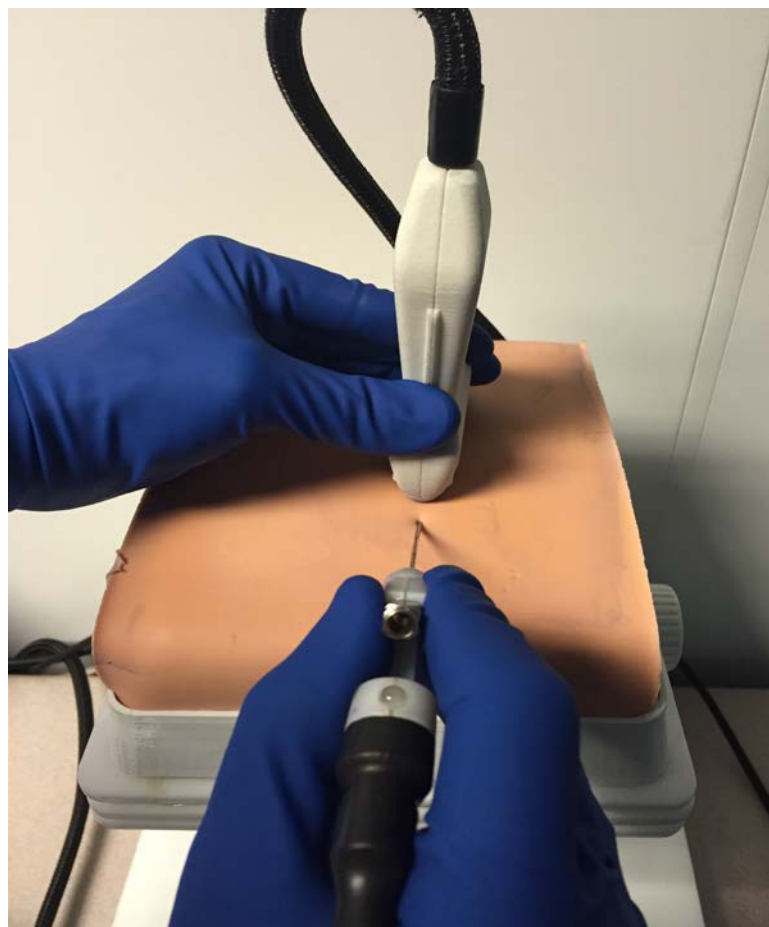
**Q20. Before advancing the needle underneath the probe, what was wrong with this picture?**

- 1). Bad external alignment and a suboptimal point of view
- 2). Nothing is wrong



**A20. Before advancing the needle underneath the probe, what was wrong with this picture?**

- 1). Bad external alignment and a suboptimal point of view



The needle hub, tip, and long axis of the probe should all be aligned before the needle advancement